

# Posttreatment endodontic disease among patients seeking treatment at a referral dental hospital in Kenya

BENJAMIN SIMIYU NYONGESA, KAARIA MWIRIGI, LAURA GWAHALLA EDALIA, BERNINA KISUMBI, TOM DIENYA

Department of Conservative and Prosthetic Dentistry, School of Dental Sciences, University of Nairobi, Nairobi, Kenya

## ABSTRACT

**Background:** The incidence of postendodontic treatment disease has equally increased in prevalence among patients with previous root-treated teeth.

**Objective:** This study aimed at determining the characteristics of post-treatment disease following endodontic treatment.

**Materials and Methods:** This was a descriptive cross-sectional study. Convenience sampling was used to select periapical radiographs of patients who needed treatment of teeth with previous root canal treatment. Data were analysed using SPSS.

**Study Benefits:** This research will aid in the development of realistic, evidence-based oral health care policies that could be integrated into general health care within the region.

**Results:** A total of 42 patients participated in the study with 54 teeth presenting with posttreatment endodontic disease (PTEDx). The ages of most patients were distributed in the range of 31–40 years with maxillary molars (25.9%) being the most commonly affected teeth. Thirty-nine (72.2%) teeth were asymptomatic, whereas 15 (27.8%) were associated with pain of varying severity. Well-defined radiolucent lesions were present in 59.3% of the cases, whereas 74.1% of the teeth presented with voids. Inadequate root-filling length (79.6%) appeared to be the most common characteristic of PTEDx.

**Conclusion:** Posttreatment disease in this sample presented with the comparatively high substandard technical quality of root fillings and restorations.

**Recommendations:** Academic institutions teaching dentistry and related authorities should collaborate managing this problem of posttreatment disease judiciously. Technical skills, technology, and performance of root canal filling procedures should be emphasized, and suitable methods should be developed in order to achieve better treatment outcomes. Further studies should be done to establish the challenges that lead to substandard root canal treatment.

**Keywords:** Endodontic retreatment, posttreatment endodontic disease, treatment outcome

## INTRODUCTION

The development of posttreatment disease after completion of root canal treatment may undermine patients' confidence in the treatment and affect acceptance of the repeat procedure. Posttreatment endodontic disease (PTEDx) is defined as a persistent endodontic infection in root-filled teeth. Its etiology is primarily a bacterial infection. Either this can be a persistent

or secondary intraradicular infection, or it may be due to extraradicular infection. Nonmicrobial factors are also a potential cause of posttreatment disease, but evidence on this is relatively weak.<sup>[1]</sup>

**Address for correspondence:** Dr. Benjamin Simiyu Nyongesa, Department of Conservative and Prosthetic Dentistry, School of Dental Sciences, University of Nairobi, P.O Box: 19676-00202, Nairobi, Kenya.  
E-mail: savedbenja@yahoo.com

Submitted: 06-Oct-2019 Revised: 05-Nov-2019 Accepted: 08-Jan-2020 Available Online: 20-Mar-2020

Access this article online	
<b>Website:</b> www.endodontologyonweb.org	<b>Quick Response Code</b> 
<b>DOI:</b> 10.4103/endo.endo_68_19	

This is an open access journal, and articles are distributed under the terms of the Creative Commons Attribution-NonCommercial-ShareAlike 4.0 License, which allows others to remix, tweak, and build upon the work non-commercially, as long as appropriate credit is given and the new creations are licensed under the identical terms.

For reprints contact: reprints@medknow.com

**How to cite this article:** Nyongesa BS, Mwirigi K, Edalia LG, Kisumbi B, Dienya T. Posttreatment endodontic disease among patients seeking treatment at a referral dental hospital in Kenya. *Endodontology* 2020;32:8-13.

The most common etiology of persistent inflammation in root canals is bacterial biofilms.<sup>[2]</sup>

Periapical periodontitis has been insinuated as “an intraradicular biofilm-stimulated chronic condition.”<sup>[3]</sup>

Epidemiological studies have shown posttreatment disease to be very common ranging from 5% to 65% of endodontically treated teeth.<sup>[4,5]</sup> In a study of the Lithuanian population, the frequency of radiographically assessed posttreatment apical periodontitis was found to be 35%.<sup>[6]</sup> Similarly, verified posttreatment apical periodontitis was observed in 40% of root-filled teeth in a Belgian population.<sup>[7]</sup> The periapical condition of nearly 600 root canal-filled teeth in Denmark<sup>[8]</sup> was compared in 1974–1975 and 1997–1998. It was observed that about 50% of the root-filled teeth presented with posttreatment apical periodontitis in both groups, whereas the incidence of posttreatment apical periodontitis in molars was 65% in both groups. The incidence of posttreatment apical periodontitis in two particular Canadian residents was 44% and 51%.<sup>[9]</sup>

Although complete healing is a possibility after root canal treatment, delayed apical healing or the persistence of inflammation is occasionally observed.<sup>[10]</sup> A probable explanation for this is that treatment may reduce but not necessarily eliminate root infection.<sup>[11]</sup> Consequently, it has been advocated that asymptomatic root-filled teeth should be radiographically assessed during a follow-up period of up to 4 years to establish whether healing has materialized or whether a posttreatment disease diagnosis can be made.<sup>[12]</sup>

Ricucci and Langeland<sup>[9]</sup> reported that the highest incidence of radiographic and clinical healing transpired when a root filling terminated 1.5 or 2 mm short of the radiographic apex. Nevertheless, in some instances, the apical part of an obturated root canal will encompass bacteria<sup>[12]</sup> that may be linked with inflammation of apical periodontal tissues thus pain.<sup>[1]</sup> Lethal bacterial components from proliferating microorganisms should not be permitted to infiltrate the periodontium in abundant amount to trigger inflammation. Studies by Torabinejad *et al.*, Chailertvanitkul *et al.*, and Clark-Holke *et al.*<sup>[13-15]</sup> have demonstrated that voids allow bacteria to move along the root filling. Thus, the apical portion of the root filling should be free from voids that could permit the dispersion of such bacterial elements.<sup>[11]</sup>

The presence of posttreatment apical periodontitis is a characteristic feature of PTEDx, which may be recurrent, emergent, or persistent. The most common indicator of treatment failure is persistent pain correlated with teeth after

surgical or nonsurgical endodontic treatment.<sup>[16]</sup> In a study by Polycarpou *et al.*, 12% of teeth presented with persistent pain after fruitful root canal treatment, whereas in another report by Ng *et al.*, the incidence of postobturation pain was 40.2%.<sup>[17,18]</sup> The factors related to have significant outcomes on postobturation pain included the severity and presence of preoperative pain,<sup>[19]</sup> presence of interappointment pain, gender, pulpal status, tooth type or location,<sup>[20]</sup> presence and size of periapical lesion, number of root canals present, intracanal irrigant and medicament, number of treatment visits, and the extent of root filling.<sup>[21,22]</sup>

Clinicians are faced with difficulties when managing posttreatment disease as it is one of the most challenging conditions in dental practice. Its management is either through periradicular surgery or nonsurgical endodontic retreatment, both of which have very high possibilities of re-establishing the healthiness of periradicular tissues and preserving tooth function.<sup>[3]</sup> One proposed approach to clean the apical region is to create a continuously tapering root canal, with the apical foramen, rather than the apical constriction, serving as the apical endpoint of preparation.<sup>[23]</sup> Another frequently used technique that is claimed to “clean” the apical region is the “apical patency concept.”<sup>[24]</sup> This idea involves the intermittent use of small files (size 10 or 15) positioned nearly 1 mm longer than the established working length to try and push any debris that has accrued through the apical foramen and allow irrigants to cleanse the whole apical region of the root canal.

Rubinstein demonstrated that after effective endodontic surgery, 97% of the cases showed radiographic features of comprehensive healing within 1 year, with an average period for lesions to heal being 7 months.<sup>[25]</sup> Large lesions of >10 mm in diameter showed healing within a period of 11 months, signifying that the time necessary to permit the healing course and bone regeneration in humans can be much lesser than 4 years. A slow healing response is as a result of overfilling or overinstrumentation, with subsequent extrusion of materials and debris during treatment.<sup>[9]</sup>

Postendodontic treatment disease has equally increased in prevalence among patients with the previous root-treated teeth.<sup>[26]</sup> It is, therefore, imperative that clinicians should be well versed with its presentation in order to effectively manage the condition. To the cream of our comprehension, there is no study that has yet evaluated the characteristics of PTEDx in Kenya. The aim of this study was, therefore, to determine the characteristics of postendodontic treatment disease among patients presenting with previous root canal treatment.

**MATERIALS AND METHODS**

Periapical radiographs of patients attending the Department of Conservative Dentistry at the University of Nairobi, School of Dental Sciences, from January 2017 to December 2018 were evaluated.

This study comprised patients who presented to the conservative clinic seeking treatment of a tooth/teeth with previous root canal treatment. The inclusion criteria were patients who consented to participate in the study and those who presented with posttreatment disease. The exclusion criteria were patients whose primary endodontic treatment was done outside Kenya, those who needed primary endodontic treatment, those with previously initiated endodontic therapy, those who did not consent to the study, and teeth with periodontal pockets deeper than 4 mm.

To collect data, a data collection sheet was used. The form was administered and filled by the researchers. Clinical and radiographic examination of patients was done, and a comprehensive history of presenting complaint was obtained and filled on the data collection form.

Extraoral examination included palpation of masticatory, neck and shoulder muscles for comparative tenderness, auscultation and palpation of the temporomandibular joint, and assessment of the range of mandibular movement. Clinical details of the treated tooth recorded included tenderness to percussion, tenderness to palpation of adjacent soft tissues, presence of an associated sinus tract, mobility, periodontal probing depths, and the presence of an adequate coronal seal.

Periapical radiographs taken as part of the investigation were examined blindly by two independent investigators under controlled conditions in a darkened room using a fluorescent light box (Rinn; DENTSPLY Ltd.) and a magnifying viewer (Brynof, 2.5 magnification; Trycare Ltd., Bradford, UK). The clinicians were precalibrated using reference radiographs representing a normal radiographic appearance of a sound tooth and an abnormal one.

This research proposal was approved by the Kenyatta National Hospital/University of Nairobi Ethical, Research and Standards Committee. Approval to conduct this research was obtained from the University of Nairobi, School of Dental Sciences. Informed consent was sought from all the participants before the study with the confidentiality of all information guaranteed. Patients with postendodontic treatment disease were treated.

The data were analyzed using SPSS, version 20.0 (Statistical Package for Social Sciences; SPSS Inc., Chicago, IL, USA) and subjected to different statistical tests.

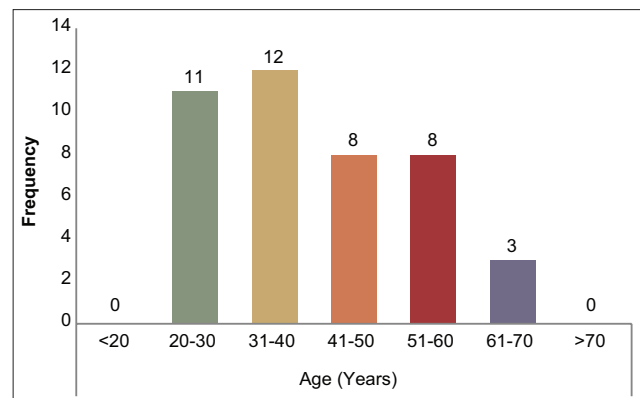
**RESULTS**

A total of 42 patients participated in the study with 54 teeth presenting with PTEDx. The age range was 20–70 years, and most patients were distributed in the 31–40-year age band [Figure 1].

Majority of the teeth (40, 74.1%) assessed were from the maxillary jaw, whereas 14 teeth (25.9%) were from the mandible. Maxillary molars (14, 25.9%) were the most commonly affected teeth, whereas only 1 (1.9%) mandibular canine was affected. No mandibular incisor with failed endodontic treatment was encountered in the study. In 24 teeth (44.5%), more than 1 year had lapsed since the time of initial endodontic treatment, whereas 16 (29.6%) teeth had been treated less than a year. The time of initial treatment could not be established in 14 teeth (25.9%) [Table 1].

**Table 1: Distribution of teeth and time since initial treatment**

Characteristics	n (%)
Time since initial treatment (year)	
≤1	16 (29.6)
>1	24 (44.5)
Unknown	14 (25.9)
Tooth location	
Maxilla	40 (74.1)
Mandible	14 (25.9)
Tooth type	
Maxillary incisors	12 (22.2)
Maxillary canines	4 (7.4)
Maxillary premolars	11 (20.4)
Maxillary molars	14 (25.9)
Mandibular incisors	0
Mandibular canines	1 (1.9)
Mandibular premolars	2 (3.7)
Mandibular molars	10 (18.5)



**Figure 1: Age distribution of participants**

Regarding the signs and symptoms, 39 teeth (72.2%) with PTEDx were asymptomatic at the time of investigation, whereas 15 (27.8%) were associated with pain of varying severity. Ten teeth (18.5%) were associated with presence of a discharging sinus tract [Table 2].

A Fisher's exact test of association showed no statistically significant association between presence of a sinus and presence of pain (Fisher's = 2.545,  $P = 0.133$ ). A Spearman's rank-order correlation showed no statistically significant association between time since initial treatment and the presence of sinus ( $r_s = -0.023$ ,  $P = 0.869$ ), tooth type and presence of a sinus ( $r_s = -0.067$ ,  $P = 0.629$ ), density of obturation and presence of a sinus ( $r_s = 0.059$ ,  $P = 0.672$ ), length of obturation and presence of a sinus ( $r_s = -0.107$ ,  $P = 0.440$ ), uninstrumented canal and presence of a sinus ( $r_s = 0.227$ ,  $P = 0.098$ ), nor between presence of a separated instrument and presence of a sinus ( $r_s = -0.229$ ,  $P = 0.095$ ).

Slightly more than half of the teeth (32, 59.3%) had been restored with either amalgam or composite coronally, 16 (29.6%) with crowns, 1 (1.9%) with a postcrown, and 3 (5.6%) with temporary restorations. The restoration used on 2 (3.7%) teeth could not be established because the restorations were missing at the time of examination and records of treatment done were not accessible.

### Radiographic evaluation

Table 3 presents the radiographic findings of the sample. Well-defined radiolucent lesions were present in 32 teeth (59.3%). A Spearman's rank-order correlation elicited a statistically significant association between presence of a sinus and presence of a periapical lesion ( $r_s = 0.298$ ,  $P = 0.028$ ). However, there was no statistically significant association between time since initial treatment and presence of periapical lesion ( $r_s = -0.267$ ,  $P = 0.051$ ), tooth type and presence of a periapical lesion ( $r_s = -0.180$ ,  $P = 0.192$ ), nor between pain and presence of a periapical lesion ( $r_s = 0.068$ ,  $P = 0.627$ ).

Majority of the teeth (34, 64.8%) exhibited signs of overhangs or open margins associated with the coronal restorations, 11 (20.4%) had no signs of overhangs or open margins, whereas 8 (14.8%) of them presented with missing coronal restorations.

The density of obturation was acceptable in 14 teeth (25.9%), whereas 40 teeth (74.1%) presented with voids. Short obturation was present in 43 teeth (79.6%), exhibiting root fillings more than 2 mm short of the radiographic apex. Only one tooth had been overfilled. A Spearman's rank-order correlation elicited

**Table 2: Signs and symptoms associated with posttreatment disease**

Characteristics	n (%)
Pain	
Mild	8 (14.8)
Moderate	4 (7.4)
Severe	3 (5.6)
No pain	39 (72.2)
Presence of sinus	
Presence of sinus	10 (18.5)
Absence of sinus	44 (81.5)

**Table 3: Radiographic evaluation of teeth with posttreatment disease**

Characteristics	n (%)
Density of obturation	
Lateral seal (root filling) with no voids seen in the root filling	14 (25.9)
Voids seen in either the coronal 1/2 of the root filling	17 (31.5)
Voids seen in the apical 1/2 of the root filling	6 (11.1)
Voids seen in both the coronal 1/2 of the root filling and in the peripheral 1/2 of the root filling	17 (31.5)
Length of obturation	
Root-filling ending >2 mm short of radiographic apex (short >2 mm)	43 (79.6)
Root-filling ending ≤2 mm from or flush with radiographic apex (within 0-2 mm)	10 (18.5)
Overfilling, root-filling material seen into the periapical bone (overextended)	1 (1.9)
Perforation	
Absent	54 (100)
Present	0
Uninstrumented canal	
Absent	44 (81.5)
Present	10 (18.5)
Separated instrument	
Absent	50 (92.6)
Present	4 (7.4)

a statistically significant association between tooth type and length of obturation ( $r_s = -0.332$ ,  $P = 0.014^*$ ).

Uninstrumented canals were detected in 10 teeth (18.5%), whereas separated instruments were evident in 4 teeth (7.4%). No perforations were detected in any of the teeth. There was a statistically significant association between tooth type and uninstrumented canal ( $r_s = 0.407$ ,  $P = 0.002$ ). There was no statistically significant association between tooth type and separated instrument ( $r_s = -0.093$ ,  $P = 0.505$ ), pain and uninstrumented canals ( $r_s = -0.159$ ,  $P = 0.250$ ), nor between pain and separated instrument ( $r_s = -0.179$ ,  $P = 0.196$ ).

### DISCUSSION

The current study investigated the characteristics of posttreatment disease following endodontic treatment.

The ages of most patients were distributed in the range of 31–40 years.

Maxillary molars were the most commonly affected teeth, a finding similar to Thampibul *et al.*, who found that molars had the highest frequency of inadequate root fillings at 61.5%.<sup>[27]</sup> This finding might be attributed to the difficulty encountered in treatment approaches.

In the present study, the majority of the teeth with PTEDx were asymptomatic at the time of investigation, and this is in agreement with a study by Kim.<sup>[28]</sup> In their study, Kim *et al.* revealed that only 5.5% of root canal-treated teeth were symptomatic compared to 27.8% in the present study. This could be because medical records were recorded using different tools and protocols. Furthermore, different pain scales could have been used.

The frequency of well-defined radiolucent lesions was lower in the present study (59.3%) compared with finding in another study (64.4%).<sup>[29]</sup> This could be as a result of periradicular lesions limited to the cancellous bone that usually pass undetected by conventional radiographic techniques.<sup>[30]</sup> Al-Nuaimi *et al.* in their study found that with preoperative cone-beam computed tomography scans, apical radiolucencies were observed in 58.5% of the teeth in the root canal treatment sample and in 86.6% of the teeth in the retreatment sample compared to 39% and 64.1% on periapical films, respectively.<sup>[29]</sup> Moreover, the microbiologic status of the root canal and apex cannot be concluded on the basis of radiographic examinations alone.<sup>[28]</sup>

Similar to a previous study,<sup>[27]</sup> majority of the failed teeth (64.8%) had defective restorations. This could be due to microleakage leading to the development of a posttreatment disease. The quality of root filling, as well as final restoration, is essential for achieving a good prognosis, a finding supported by previous studies.<sup>[27]</sup>

Regarding the density of obturation, the majority of the teeth had voids, a factor that jeopardizes the integrity of the root filling. This outcome was also consistent with related studies.<sup>[27]</sup> These studies emphasized the significance of a good technical quality root filling to enhance an effective seal in endodontically treated teeth.<sup>[27]</sup>

In the present study, the majority of the teeth (79.6%) presenting with PTEDx had a substandard length of root filling. A similarly high prevalence has also been reported in other studies<sup>[28,31]</sup> and could be considered the primary factor responsible for the high frequency of failure. Teeth with short

obturation failed more because of inadequate biomechanical preparation and disinfection in the apical segment and a lack of bacteria-tight seal serving as a potential reservoir for microorganisms colonizing the periapical tissue.<sup>[32]</sup>

More than 1 year had elapsed since the time of initial endodontic treatment for majority (44.5%) of the failed cases. However, in a study by Petersson *et al.*,<sup>[26]</sup> the overall outcome did not differ significantly after an 11-year follow-up. This outcome is because the number of endodontically treated teeth with healed periapical disease was nearly the same as the number of those with newly established disease. The time of initial treatment could not be established in 25.9% of the teeth. Cross-sectional studies gather data within a particular timeframe without knowing their temporal relationships.<sup>[33]</sup> Therefore, one critical limitation of the current study is that the time elapsed between endodontic treatment and radiographic image acquisition was not specified. When the date of treatment is unspecified, the frequency of posttreatment disease may be overestimated because clinicians are unable to establish whether lesions were healing.<sup>[34]</sup> Therefore, based on the limits coupled with this type of study, the data must be inferred with caution.

## CONCLUSION

Posttreatment disease in this Kenyan sample population presented with relatively high substandard technical quality of root fillings and restorations.

## Recommendation

Academic institutions teaching dentistry and related authorities should collaborate managing this problem of posttreatment disease judiciously. Technical skills, technology, and performance of root canal filling procedures should be emphasized, and suitable methods should be developed in order to achieve better treatment outcomes.

Further studies should be done within the study area to establish the challenges which lead to substandard root canal treatment with the aim of coming up with solutions to ensure root canal treatment that is performed to a good standard.

## Acknowledgment

The authors would like to thank the University of Nairobi, School of Dental Sciences, for allowing us to contact this study.

## Financial support and sponsorship

Nil.



**Conflicts of interest**

Nil.

**REFERENCES**

1. Nair PN. Pathogenesis of apical periodontitis and the causes of endodontic failures. *Crit Rev Oral Biol Med* 2004;15:348-81.
2. Strindberg LZ. The dependence of the results of pulp therapy on certain factors: An analytic study based on radiographic and clinical follow-up examination. *Acta Odontol Scand* 1956;21:1-75.
3. Siqueira JF Jr., Rôças IN, Ricucci D, Hülsmann M. Causes and management of post-treatment apical periodontitis. *Br Dent J* 2014;216:305-12.
4. Costerton JW, Stewart PS, Greenberg EP. Bacterial biofilms: A common cause of persistent infections. *Science* 1999;284:1318-22.
5. Spangberg LS, Haapasalo M. Rationale and efficacy of root canal medicaments and root filling materials with emphasis on treatment outcome. *Endod Topics* 2002;2:35-58.
6. Trope M, Bergenholtz G. Microbiological basis for endodontic treatment: Can a maximal outcome be achieved in one visit. *Endod Topics* 2002;1:40-53.
7. Haapasalo M, Dunæs T, Endal U. Persistent, recurrent, and acquired infection of the root canal system post-treatment. *Endod Topics* 2003;6:29-56.
8. Bergenholtz G, Spångberg L. Controversies in endodontics. *Crit Rev Oral Biol Med* 2004;15:99-114.
9. Ricucci D, Langeland K. Apical limit of root canal instrumentation and obturation, part 2. A histological study. *Int Endod J* 1998;31:394-409.
10. Simon JH. The apex: How critical is it? *Gen Dent* 1994;42:330-4.
11. Wu MK, Dummer PM, Wesselink PR. Consequences of and strategies to deal with residual post-treatment root canal infection. *Int Endod J* 2006;39:343-56.
12. Nair PN, Sjögren U, Krey G, Kahnberg KE, Sundqvist G. Intracellular bacteria and fungi in root-filled, asymptomatic human teeth with therapy-resistant periapical lesions: A long-term light and electron microscopic follow-up study. *J Endod* 1990;16:580-8.
13. Torabinejad M, Ung B, Kettering JD. *In vitro* bacterial penetration of coronally unsealed endodontically treated teeth. *J Endod* 1990;16:566-9.
14. Chailertvanitkul P, Saunders WP, Saunders EM, MacKenzie D. An evaluation of microbial coronal leakage in the restored pulp chamber of root-canal treated multirooted teeth. *Int Endod J* 1997;30:318-22.
15. Clark-Holke D, Drake D, Walton R, Rivera E, Guthmiller JM. Bacterial penetration through canals of endodontically treated teeth in the presence or absence of the smear layer. *J Dent* 2003;31:275-81.
16. Hoskinson SE, Ng YL, Hoskinson AE, Moles DR, Gulabivala K. A retrospective comparison of outcome of root canal treatment using two different protocols. *Oral Surg Oral Med Oral Pathol Oral Radiol Endod* 2002;93:705-15.
17. Polycarpou N, Ng YL, Canavan D, Moles DR, Gulabivala K. Prevalence of persistent pain after endodontic treatment and factors affecting its occurrence in cases with complete radiographic healing. *Int Endod J* 2005;38:169-78.
18. Ng YL, Glennon JP, Setchell DJ, Gulabivala K. Prevalence of and factors affecting post-obturation pain in patients undergoing root canal treatment. *Int Endod J* 2004;37:381-91.
19. Fox J, Atkinson JS, Dinin AP, Greenfield E, Hechtman E, Reeman CA, et al. Incidence of pain following one-visit endodontic treatment. *Oral Surg Oral Med Oral Pathol* 1970;30:123-30.
20. Genet JM, Wesselink PR, Thoden van Velzen SK. The incidence of preoperative and postoperative pain in endodontic therapy. *Int Endod J* 1986;19:221-9.
21. Yesilsoy C, Koren LZ, Morse DR, Rankow H, Bolanos OR, Furst ML. Post-endodontic obturation pain: A comparative evaluation. *Quintessence Int* 1988;19:431-8.
22. Albashairh ZS, Alnegrish AS. Postobturation pain after single-and multiple-visit endodontic therapy. A prospective study. *J Dent* 1998;26:227-32.
23. Buchanan LS. The standardized-taper root canal preparation – Part 1. Concepts for variably tapered shaping instruments. *Int Endod J* 2000;33:516-29.
24. Cailleteau JG, Mullaney TP. Prevalence of teaching apical patency and various instrumentation and obturation techniques in United States dental schools. *J Endod* 1997;23:394-6.
25. Rubinstein RA, Kim S. Short-term observation of the results of endodontic surgery with the use of a surgical operation microscope and Super-EBA as root-end filling material. *J Endod* 1999;25:43-8.
26. Petersson K, Håkansson R, Håkansson J, Olsson B, Wennberg A. Follow-up study of endodontic status in an adult Swedish population. *Endod Dent Traumatol* 1991;7:221-5.
27. Thampibul P, Jantarat J, Arayasantiparb R. Post-treatment apical periodontitis related to the technical quality of root fillings and restorations in Thai population. *Aust Endod J* 2019;45:163-70.
28. Kim S. Prevalence of apical periodontitis of root canal-treated teeth and retrospective evaluation of symptom-related prognostic factors in an urban South Korean population. *Oral Surg Oral Med Oral Pathol Oral Radiol Endod* 2010;110:795-9.
29. Al-Nuaimi N, Patel S, Davies A, Bakhsh A, Foschi F, Mannocci F. Pooled analysis of 1-year recall data from three root canal treatment outcome studies undertaken using cone beam computed tomography. *Int Endod J* 2018;51 Suppl 3:e216-26.
30. Ray HA, Trope M. Periapical status of endodontically treated teeth in relation to the technical quality of the root filling and the coronal restoration. *Int Endod J* 1995;28:12-8.
31. Siqueira JF Jr., Rôças IN, Alves FR, Campos LC. Periradicular status related to the quality of coronal restorations and root canal fillings in a Brazilian population. *Oral Surg Oral Med Oral Pathol Oral Radiol Endod* 2005;100:369-74.
32. Sjogren U, Hagglund B, Sundqvist G, Wing K. Factors affecting the long-term results of endodontic treatment. *J Endod* 1990;16:498-504.
33. Eriksen HM, Kirkevang LL, Petersson K. Endodontic epidemiology and treatment outcome: General considerations. *Endod Topics* 2002;2:1-9.
34. Hülsmann M. Epidemiology of post-treatment disease. *Endod Topics* 2016;34:42-63.